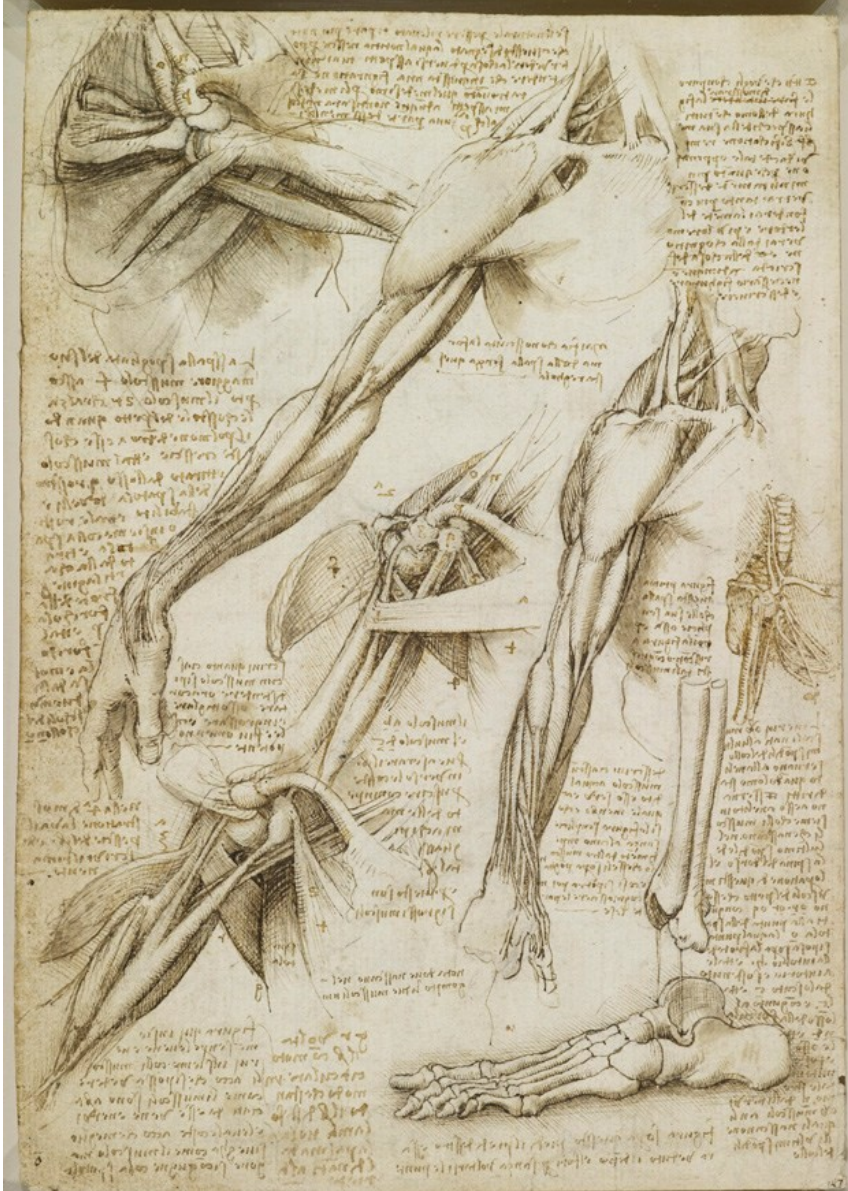
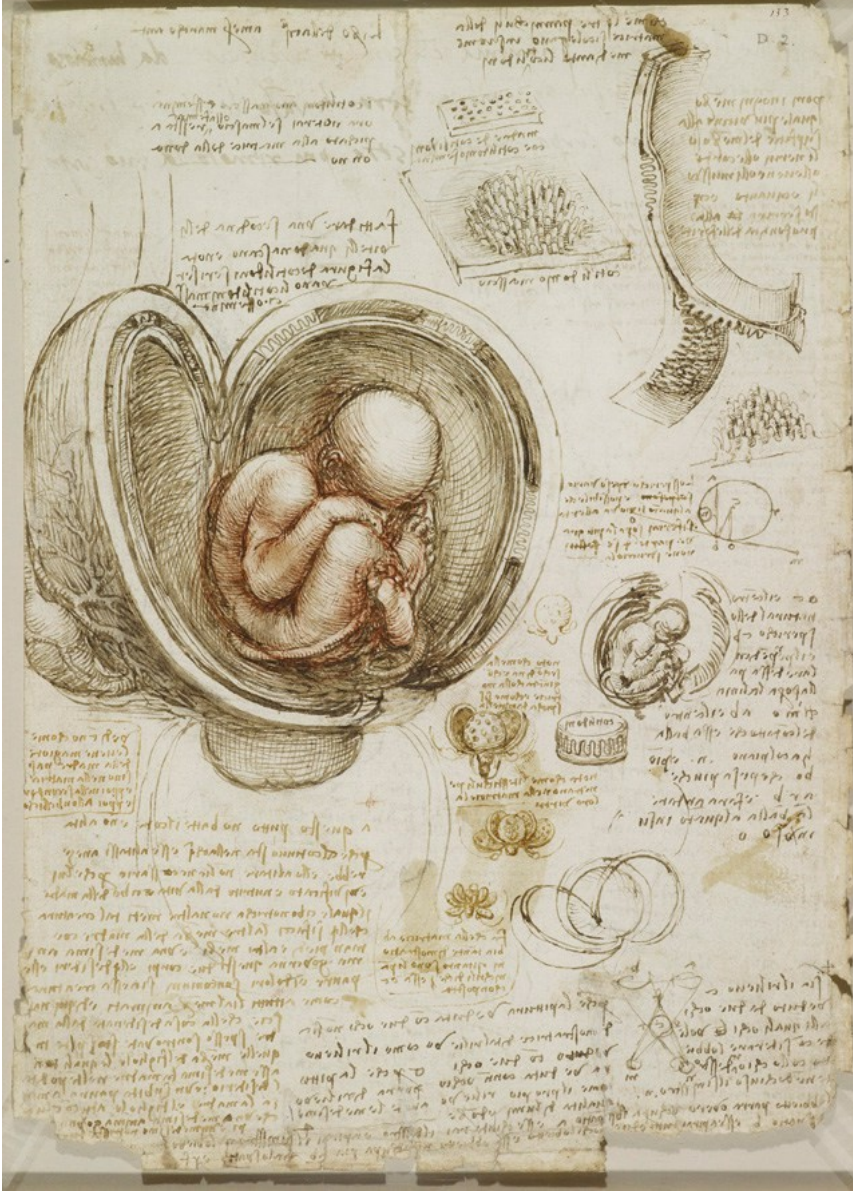
A Selection of
Leonardo Da Vinci's
Anatomy Drawings



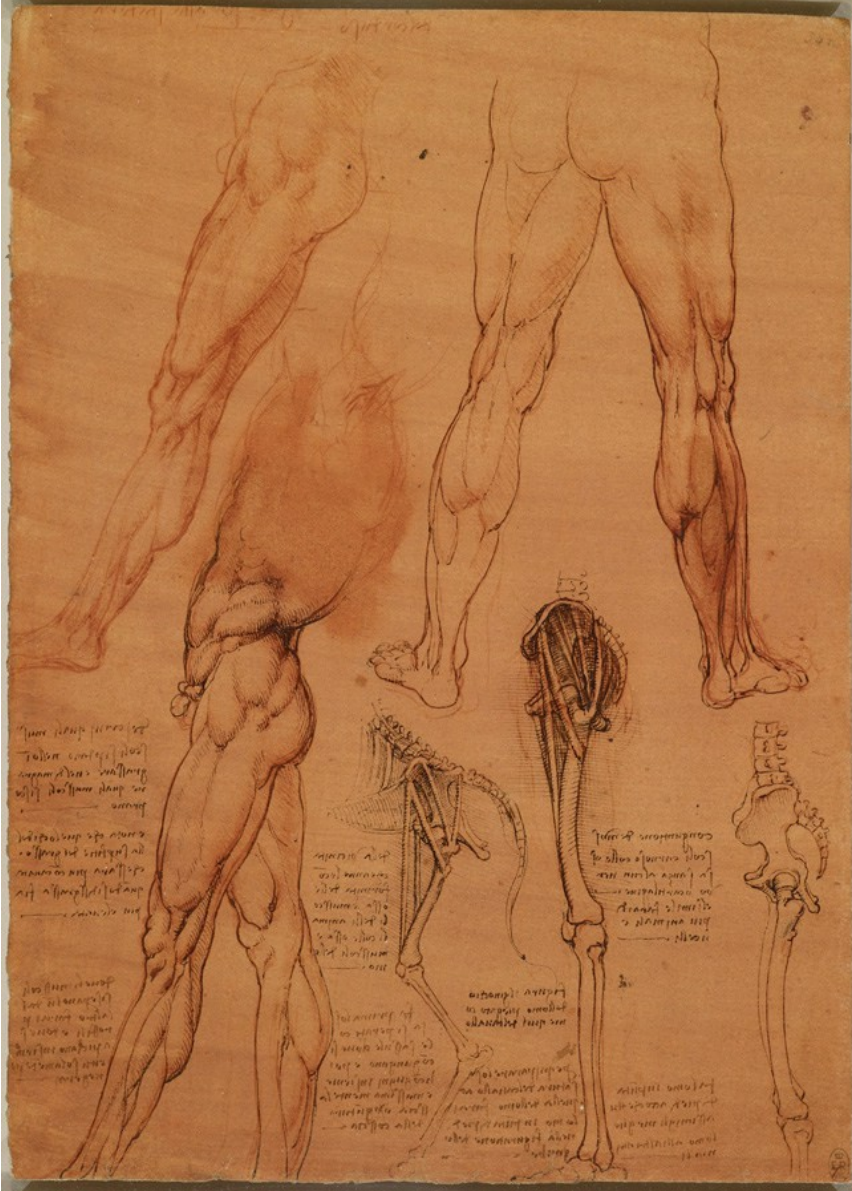
Three studies, one on a larger scale, of a man's right arm and shoulder, showing muscles; three studies of a right arm; a diagram to illustrate pronation and supination of the hand.

Royal Collection © Her Majesty Queen Elizabeth II



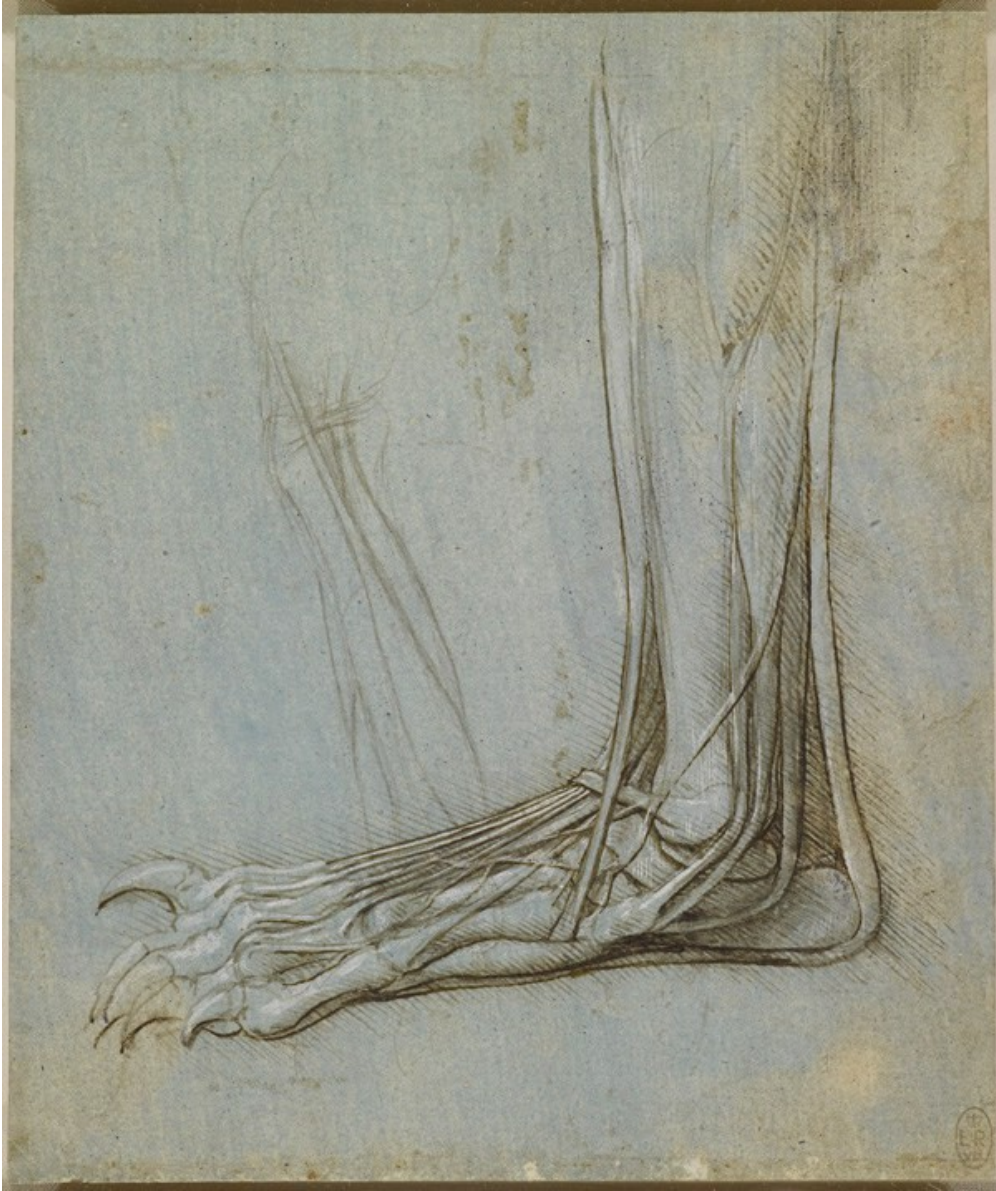Large drawing of an embryo within a human uterus with a cow's placenta; smaller sketch of the same; notes on the subject; illustrative drawings in detail of the placenta and uterus; diagram demonstrating binocular vision; a note on relief in painting and on mechanics.

Royal Collection © Her Majesty Queen Elizabeth II



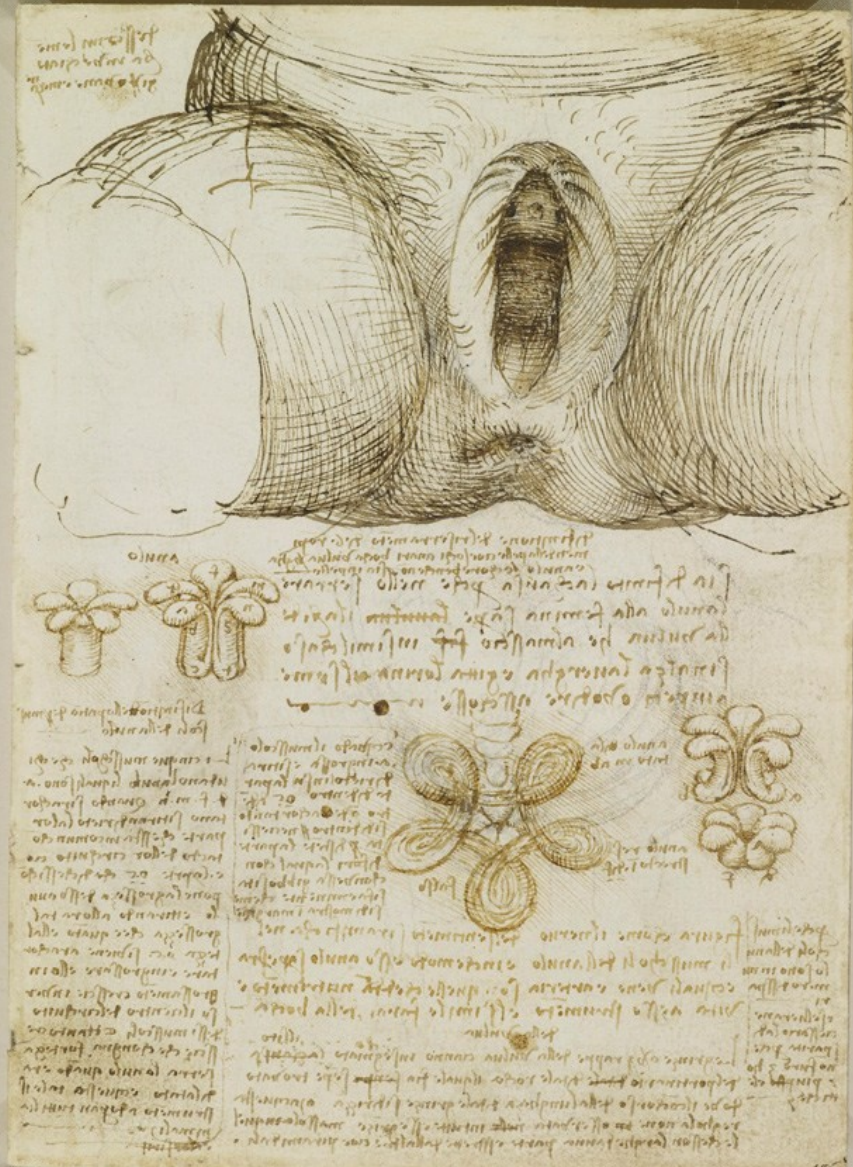
A study of a man's left leg, stretched forward; beside it, a man's legs seen from behind; below is a man standing, turned in profile to the left, with his left leg advanced; to the right are two studies of the bones of human left legs and thighs, and one of an animal; with many notes on the muscles.

Royal Collection © Her Majesty Queen Elizabeth II



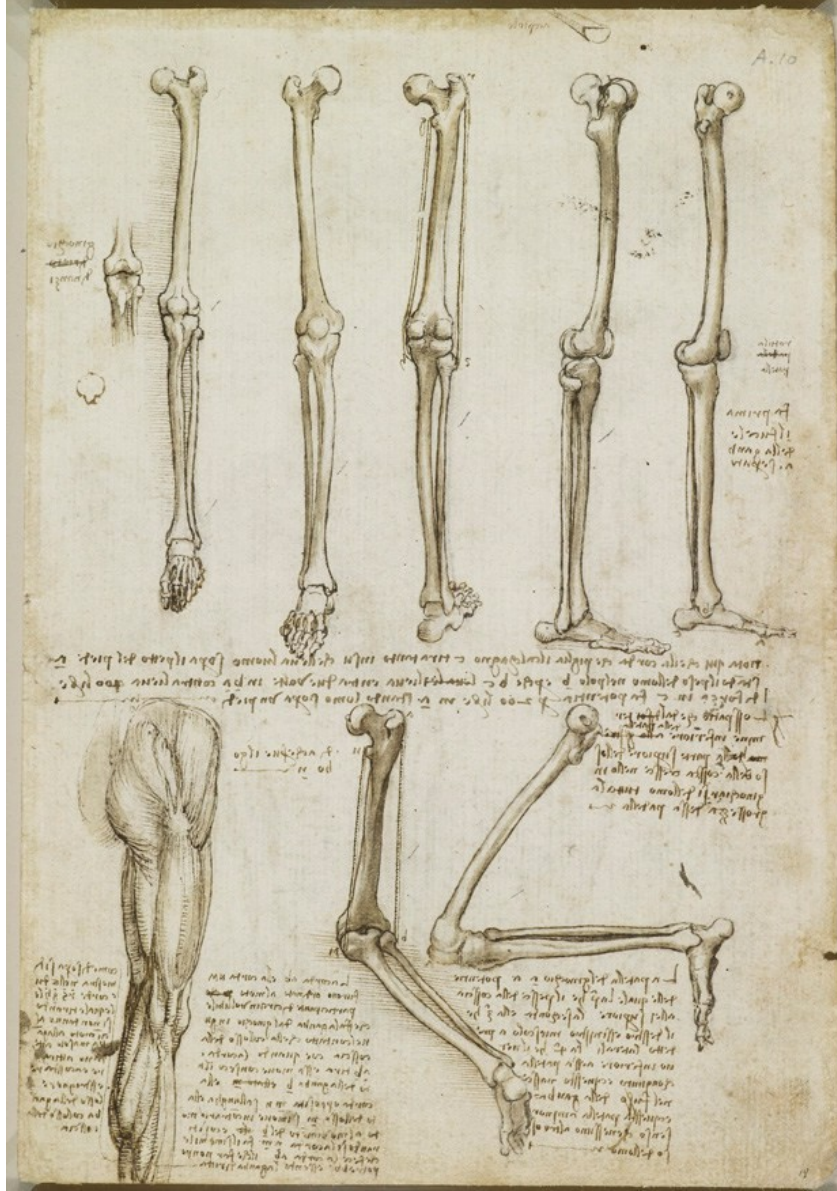
A study of the dissection of the lower leg and foot of a bear, viewed in profile to the left. To the left there is also a slight drawing of the leg.

Royal Collection © Her Majesty Queen Elizabeth II



Drawing of external genitalia and vagina, with notes; notes on the anal sphincter and diagrams of suggested arrangement of its fibers and its mode of action.

Royal Collection © Her Majesty Queen Elizabeth II



Five studies of the bones of the leg and foot; a drawing of the knee joint and patella; two studies of the bones of a right leg with the knee flexed; the muscles of a right buttock, thigh and calf.

Royal Collection © Her Majesty Queen Elizabeth II